




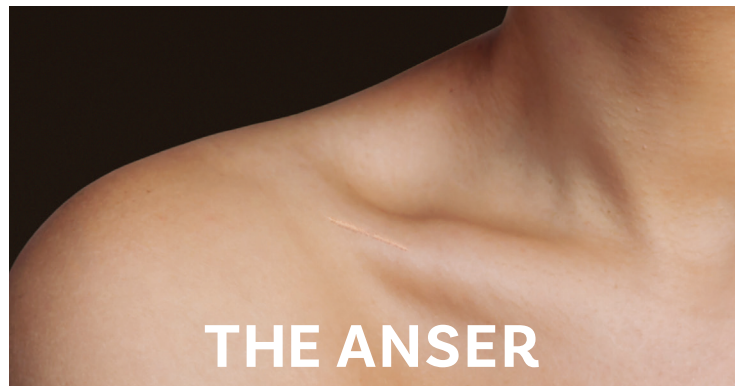
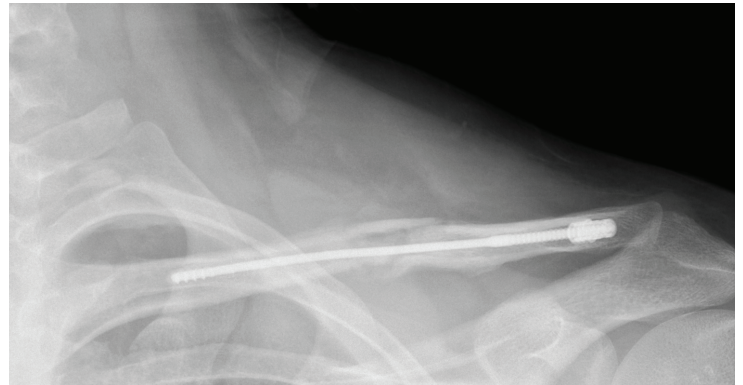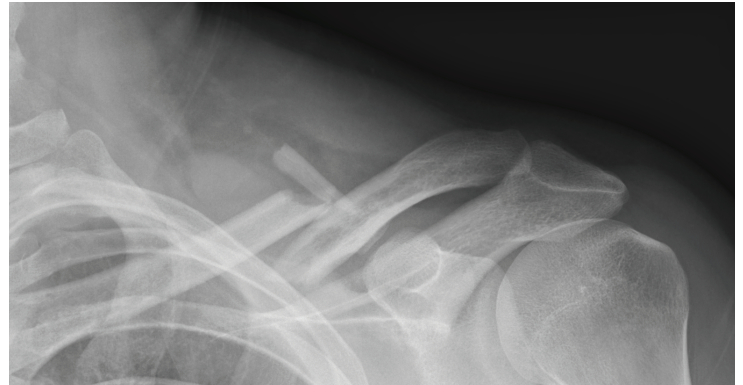
SURGICAL TECHNIQUE
ANSER CLAVICLE PIN SET
FOR MIDSHAFT CLAVICLE FRACTURES*



**Intended for healthcare professionals.*

Table of Contents

| | |
|---------------------------------|----|
| Intended Use..... | 3 |
| Indications for Use | 3 |
| Contraindications..... | 3 |
| Introduction | 3 |
| Features and Benefits..... | 3 |
| Design Philosophy..... | 4 |
| Set Description..... | 5 |
| Surgical Technique | 6 |
| Warnings..... | 11 |
| Magnetic Resonance Imaging..... | 12 |
| Implant Removal..... | 12 |
| References | 14 |
| Literature..... | 14 |
| Figures | 15 |
| Manufacturer | 15 |
| Notes | 16 |



Intended Use

The Anser Clavicle Pin Set is an intramedullary fixation device, intended for fixation of midshaft clavicle fractures. The goal of the Anser Clavicle Pin Set is to restore the native length and alignment of the fractured midshaft clavicle in a minimally invasive manner.

Indications for Use

The Anser Clavicle Pin is intended to be used to repair an acute fracture, mal-union or non-union of the clavicle.

Contraindications

- Patients suffering from (severe) osteoporosis
- Patients who are not fit for surgery
- Patients who are not skeletally mature
- Possible non-compliant patients (e.g. due to alcohol and drug addiction, dementia)
- Additional neurovascular injury
- Pathologic fractures

Introduction

Fractures of the clavicle are common, comprising up to 5% of all fractures in adults [1]. Most clavicle fractures are localized at the level of the mid-diaphyseal third [2].

Because of the specific sigmoid shaped anatomy and muscle insertions the majority of these fractures are displaced and/or shortened. These factors have been found to be predictors of poorer outcomes concerning nonunions, persistent post traumatic symptoms and cosmetics in conservatively treated midshaft clavicle fractures (MSCF) [3,4,5].

Several surgical treatment options exist, such as fixation by means of plate and screw constructs or by means of intramedullary devices. These are generally associated with good clinical outcomes. However, these devices are also subject to a specific array of drawbacks and complications [25]. The Anser Clavicle Pin set is thoughtfully designed to address these specific disadvantages while combining the advantages of current treatment options.

The Anser Clavicle Pin is intended to be used by Orthopaedic, Trauma, Upper extremity/Shoulder, Sports Medicine, General Orthopaedic or General surgeons in an Operating Room.

Features and Benefits

The design of the Anser Clavicle Pin consists of a 2.2 mm flexible pin fabricated from a titanium alloy (Ti-6Al-4V). The Anser Clavicle Pin has a blunt tip which helps prevent perforation. The threaded tip anchors itself against the cortical bone in the medial fracture element.

The Anser Clavicle Pin has a plurality of indentations. These allow the surgeon to adjust the optimal length of the fractured clavicle and the Anser Clavicle Pin intra-operatively.

The Anser Lateral Fixation Device consists of a threaded exterior and six resilient legs. The Anser Lateral Fixation Device anchors itself into the cortical bone of the lateral fracture element by means of the coarse thread. Simultaneously, the resilient legs position themselves around the Anser Clavicle Pin in one of the previously mentioned indentations. Once the optimal length and alignment of the clavicle has been obtained the construct is secured with the Anser End Cap. The Anser Clavicle Pin is cut to length.



Design Philosophy


The Anser Clavicle Pin is designed based on the premise that midshaft clavicle fractures do not need absolute stability for proper healing. The fractured clavicle needs to be realigned and kept at length until union occurs. Therefore fixation on both sides of the fracture is required. The design is flexible to follow the contour of the clavicle during insertion and rigid to maintain reduction. The Anser Clavicle Pin is intended as a one-size-fits-all device.

During rehabilitation and movement of the arm and shoulder the clavicle rotates around its longitudinal axis. When fractured, the fracture elements can rotate to a different extent or in opposite directions. To prevent possible friction on the bone-implant interface, loosening of the implant, or hardware failure, the Anser Lateral Fixation Device will allow rotation around the Anser Clavicle Pin while continuing to secure the optimal length. The torsional forces will dissipate within the implant-implant interface.








Besides excellent functional outcomes and patient satisfaction the design of the Anser Clavicle Pin Set is expected to reduce the need for hardware removal. This may lead to a reduction in reoperations and associated morbidity [26].

Set Description

The Anser Clavicle Pin Set

| REF | Name | Image | Contents | Qty. |
|----------|------------------------|--|-------------------------------|------|
| ANS-501S | Anser Clavicle Pin Set |  | Anser Clavicle Pin | 1 |
| | | | Anser Lateral Fixation Device | 1 |
| | | | Anser End Cap | 1 |

The Anser Instrument Set

| REF | Instrument | Image | Functions | Qty. |
|-----------|--|--|--|------|
| ANS-602 | Anser Manual Pin Driver |  | Manual insertion of the Anser Clavicle Pin | 1 |
| ANS-603 | Anser Tap |  | Tapping thread for the Anser Lateral Fixation Device | 1 |
| ANS-604 | Anser Lateral Fixation Device Inserter |  | Insertion of the Anser Lateral Fixation Device | 1 |
| ANS-605 | Anser End Cap Inserter |  | Application of the Anser End Cap | 1 |
| 310.401 | Drill Bit |  | Connected to a power tool to drill a hole in the cortex to provide access to the medullary canal | 1 |
| 95-186.01 | Drill Guide |  | Guide the drilling with the Drill Bit and protect the surrounding tissue | 1 |
| ANS-701 | Anser Tray |  | Facilitate cleaning, sterilization, transportation, and presentation of the instruments | 1 |



Only use instruments and accessories listed in the surgical technique to avoid adversely affecting device performance or surgical outcome. The surgical team must verify that the instruments are in good condition and in operating order prior to use during surgery.

Surgical Technique

1. The patient is positioned so that proper exposure and access to the posterolateral clavicle can be obtained. For example, the patient can be positioned in beach chair on Allen or Shoulder table which allows for removal of the shoulder part. Alternatively on a radiolucent table with a bump between the shoulder blades. (Fig. 1)

In line with common practice worldwide, it is recommended to use perioperative antibiotic prophylaxis when implanting medical devices.

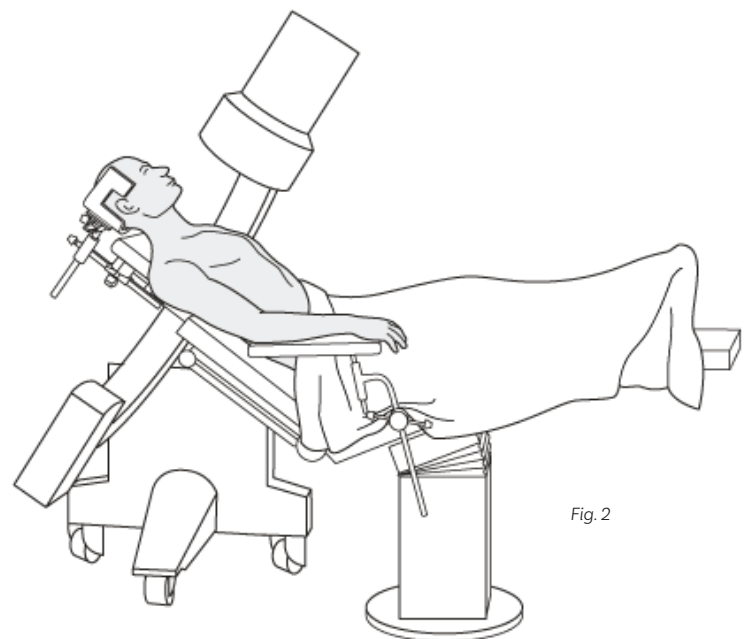
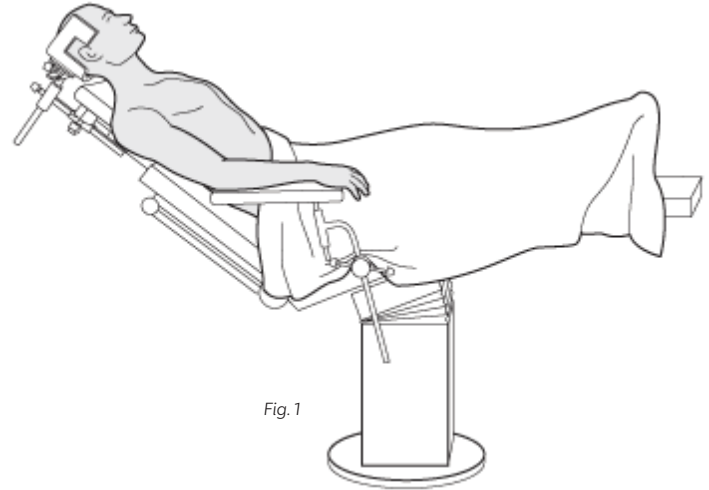
2. Identification and marking of the anatomic landmarks including clavicle, AC joint, scapular spine, posterior conoid tubercle, acromion.

3. Position and test the C-arm/fluoroscopy. (Fig. 2)

4. Determine and mark the location of the skin incision. The skin incision is made over the posterior conoid tubercle.

5. Prep and drape the surgical field in the usual sterile fashion.

6. Make a 2–3 cm incision through skin and subcutaneous tissue at the previously determined location. Direct the dissection medially towards the posterior conoid tubercle. Do not open the AC joint. Palpate the posterior conoid tubercle and the overlying fascia of the trapezius muscle.



Surgical Technique

- 7.** Open the fascia/insertion of the trapezius muscle and peel this off anteriorly and superiorly. This will allow for direct access to the posterior conoid tubercle. (Fig. 3)
- 8.** Place retractors superior and inferior of the posterior conoid tubercle to adequately visualize the appropriate entry point. With Drill Bit with the Drill Guide on the posterior conoid tubercle, the appropriate entry point can be verified by means of fluoroscopy in two directions.
- 9.** Use the 4 mm Drill Bit with the Drill Guide (tissue-protector) to open the cortex of the posterior conoid tubercle and enter the medullary canal of the lateral fracture element. The appropriate entry point is at or slightly inferior of the equator of the posterior conoid tubercle. Start drilling perpendicular to the primary cortex and slowly adjust the angle of the drill towards the direction of the medullary canal. (Fig. 4)

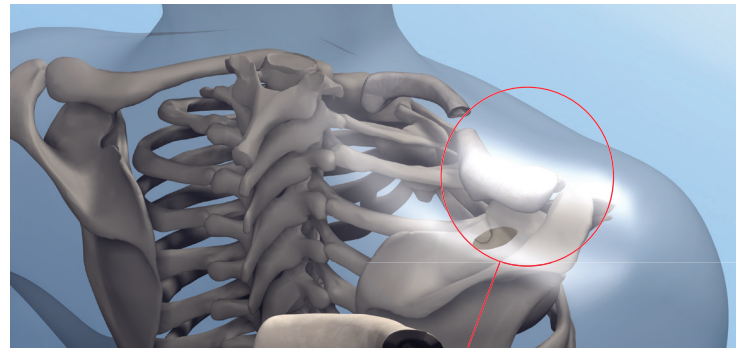


Fig. 3

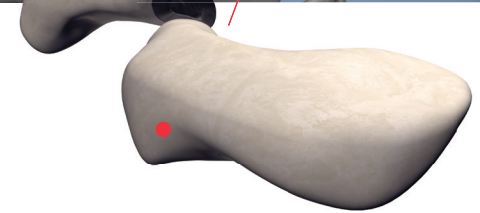
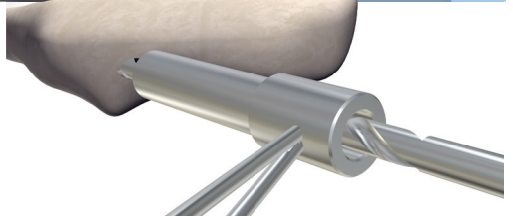


Fig. 4



The use of a powered instrument for drilling or driving the clavicle pin in position can damage the anatomical structures or damage the implant or instruments.

- 10.** While keeping the Drill Guide (tissue-protector) in place, remove the drill. This can assist with proper insertion of the Anser Clavicle Pin.
- 11.** Advance the Anser Clavicle Pin into the lateral fracture element. (Fig. 5)
- 12.** Check the position and direction of the Anser Clavicle Pin inside the lateral fracture element by means of fluoroscopy in two directions.

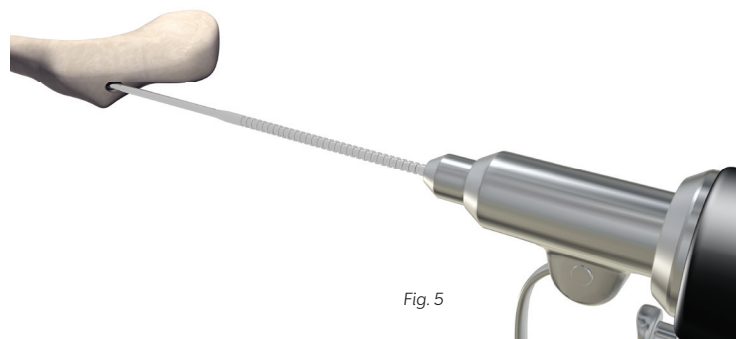


Fig. 5

Surgical Technique

13. Advance the Anser Clavicle Pin until the fracture site is reached using either the Anser Manual Pin Driver or powered universal pin driver. (Fig. 6)

14. Reduce the fracture elements and align them percutaneously using reduction clamps and reduction maneuvers. If not possible, make an accessory 2–3 cm incision over the fracture site.




Fig. 6



Proper alignment of the fracture elements before traversing the fracture site with the Anser Clavicle Pin is of utmost importance. Failure to align the fragments may lead to complications such as damage to the subclavian artery or the lung.



Equivalent intramedullary implants have a reported risk of hardware failure. The risk exists that the pin may plastically deform or break due to peak loading.

Do not use the Anser Clavicle Pin as a lever or “joystick” during reduction. It may deform or break. (Fig. 6)

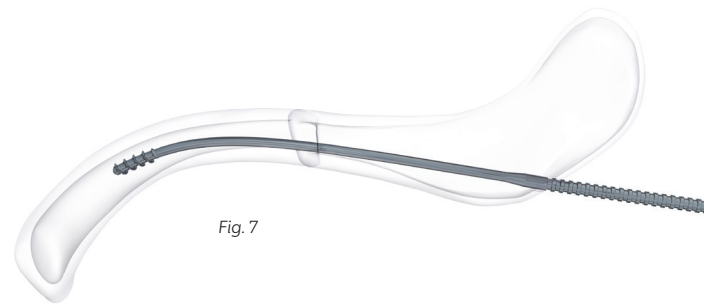


Fig. 7

15. Advance the Anser Clavicle Pin into medial fracture fragment in an oscillating fashion to prevent damage to the soft tissues around the fracture site. (Fig. 7)

16. Verify the position of the Anser Clavicle Pin by means of fluoroscopy in two directions.

17. If closed reduction attempts are unsuccessful consider making a 2–3 cm incision over the fracture site. Reduce the fracture and slowly advance the Anser Clavicle Pin into medial fracture fragment under visual control.

Surgical Technique

- 18.** Once across the fracture site manually advance the Anser Clavicle Pin towards the SC joint using the Anser Manual Pin Driver. Optimal position is approximately 1–2 cm from the SC joint and when adequate purchase is obtained. (Fig. 8)

PRECAUTION: The medial thread is designed to anchor itself against the anterior cortex of the medial fragment. It is insufficient to pull the Anser Clavicle Pin forward.

- 19.** Verify the position of the Anser Clavicle Pin by means of fluoroscopy in two directions.

- 20.** Use the Anser Tap to prepare a functional thread in the cortex of the posterior conoid tubercle. This will facilitate placement of the Anser Lateral Fixation Device.

While inserting the Anser Tap apply continuous co-linear pressure, in order to engage and maximize the creation of a functional thread.




Fig. 8



Fig. 9



If the extracortical portion of the Anser Clavicle Pin is plastically deformed, unintentional advancement of the Anser Clavicle Pin may occur when using the Anser Tap. Adjust or replace the Anser Clavicle Pin if plastically deformed or damaged.

- 21.** Use the cannulated Anser Lateral Fixation Device Inserter to place the Anser Lateral Fixation Device over the Anser Clavicle Pin. (Fig. 9)




Fig. 10



In case of incorrect positioning of the Anser Lateral Fixation Device it is not possible to place the Anser End Cap.

Ascertain the six resilient legs of the Anser Lateral Fixation Device have positioned themselves in one of the indentations of the Anser Clavicle Pin. (Fig. 10, 11)




Fig. 11

Surgical Technique

- 22.** A black engraved marker on the Anser Lateral Fixation Device Inserter indicates where the distal end of the Anser End Cap will be located in relation to the Anser Lateral Fixation Device. The marker may be used to identify the part of the Anser End Cap that is extracortical. (Fig. 12)



Avoid, if possible, using multiple insertion attempts during placement of the Anser Clavicle Pin in the medial fragment and placement of the Anser Lateral Fixation Device in order to prevent weakening/destruction of the (self-) tapped threaded interfaces.

- 1** Anser Lateral Fixation Device resilient legs should be straight, clear of debris, and placed into indentations of Anser Clavicle Pin. The marking on the resilient legs should line up with the indentation.
- 23.** Check the reduction of the fracture elements and, when aligned and deemed at length, place the Anser End Cap using the Anser End Cap Inserter.

- 24.** Advance the Anser End Cap until a click is felt and/or heard.

When the Anser Lateral Fixation Device is placed relatively deep into the lateral cortex, the Anser End Cap may be blocked by the cortex. In this case manipulate the Anser End Cap inserter until it clears the cortex and the Anser End Cap can be advanced. (Fig. 13)

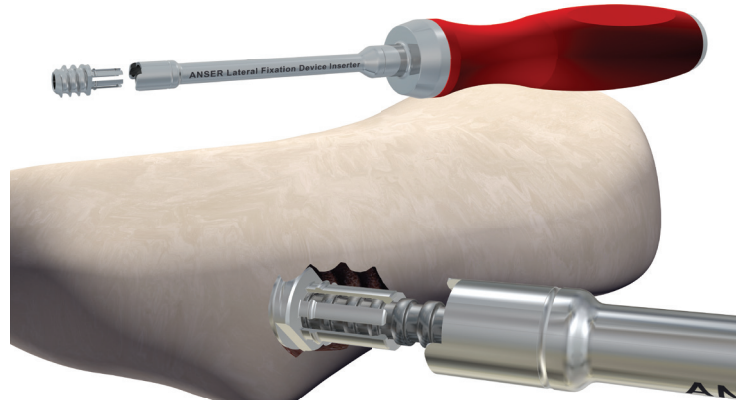


Fig. 12




Fig. 13

Surgical Technique

- 25.** Placement of the Anser End Cap secures the length of the Anser Clavicle Pin.
- 26.** Cut the Anser Clavicle Pin to length flush to the Anser End Cap using a universal pin cutter. (Fig. 14)
- 27.** Obtain final fluoroscopy images of the position of the Anser Clavicle Pin and fracture elements in two directions.
- 28.** Irrigate the surgical field and close the incisions. Apply dressings.

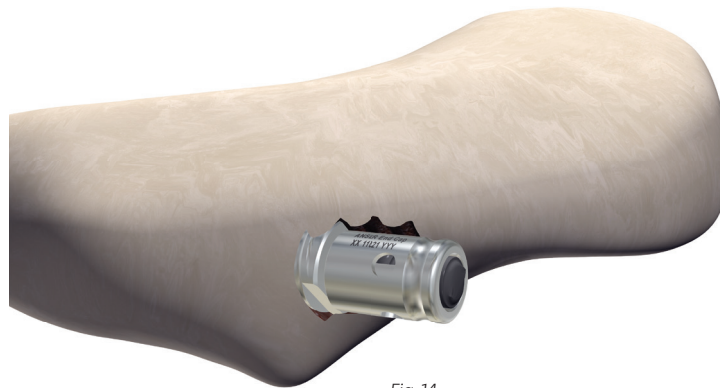

Fig. 14

WARNINGS

- 1.** Only use instruments and accessories listed in the surgical technique to avoid adversely affecting device performance or surgical outcome. The surgical team must verify that the instruments are in good condition and in operating order prior to use during surgery.
- 2.** The use of a powered instrument for drilling or driving the clavicle pin in position can damage the anatomical structures or damage the implant or instruments.
- 3.** Proper alignment of the fracture elements before traversing the fracture site with the clavicle pin is of utmost importance. Failure to align the fragments may lead to complications such as damage to the subclavian artery or the lung.
- 4.** Equivalent intramedullary implants have a reported risk of hardware failure. The risk exists that the pin may plastically deform or break due to peak loading.
Do not use the clavicle pin as a lever or “joystick” during reduction. It may deform or break.
- 5.** If the extracortical portion of the clavicle pin is plastically deformed, unintentional advancement of the clavicle pin may occur when using the Anser Tap. Adjust or replace the clavicle pin if plastically deformed or damaged.
- 6.** In case of incorrect positioning of the Anser Lateral Fixation Device it is not possible to place the Anser End Cap. Ascertain the six resilient legs of the Anser Lateral Fixation Device have positioned themselves in one of the indentations of the clavicle pin.
- 7.** Avoid, if possible, using multiple insertion attempts during placement of the clavicle pin in the medial fragment and placement of the Anser Lateral Fixation Device in order to prevent weakening/destruction of the (self-) tapped threaded interfaces.

Magnetic Resonance Imaging

The Anser Clavicle Pin has not been evaluated for safety and compatibility in the MR environment. It has not been tested for heating, migration, or image artefact in the MR environment. The safety of the Anser Clavicle Pin in the MR environment is unknown. Scanning a patient who has this device may result in patient injury.

Implant Removal

The Anser Clavicle Pin is intended not to be removed. The expected implantation time is permanent (long-term use). If need for removal occurs, the following instructions can be used.

- 1.** The patient is positioned so that proper exposure and access to the posterolateral clavicle can be obtained. For example, the patient can be positioned in beach chair on Allen or Shoulder table which allows for removal of the shoulder part. Alternatively on a radiolucent table with a bump between the shoulder blades. (Fig. 1)

In line with common practice worldwide, it is recommended to use perioperative antibiotic prophylaxis when implanting medical devices.

- 2.** Identification and marking of the anatomic landmarks including clavicle, AC joint, scapular spine, posterior conoid tubercle, acromion.
- 3.** Position and test the C-arm/fluoroscopy.
- 4.** Prep and drape the surgical field in the usual sterile fashion.
- 5.** Incise previous scar over the posterior conoid tubercle and dissect through the subcutaneous tissue towards the posterior conoid process.
- 6.** Open the fascia/insertion of the trapezius muscle and peel this off anteriorly and superiorly. This will obtain direct access to the posterior conoid tubercle and Anser End Cap.
- 7.** Place retractors superior and inferior of the posterior conoid tubercle.
- 8.** Identify the Anser End Cap and remove using pliers or forceps by pulling it away along the longitudinal axis from the Anser Lateral Fixation Device.

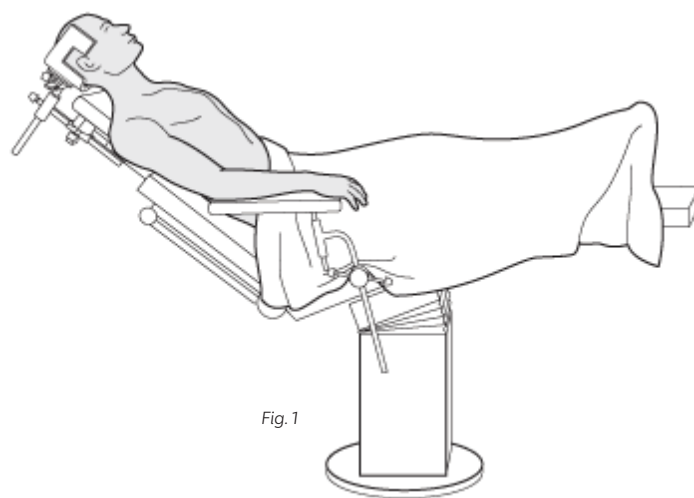


Fig. 1



Implant Removal

- 9.** Use the Anser Lateral Fixation Device Inserter to back out and remove the Anser Lateral Fixation Device. Now the residual extracortical part of the Anser Clavicle Pin should be exposed and visible.
- 10.** Use needle nose pliers or extraction pliers (as used for removal of Titanium Elastic Nails), vice grip, T-handle chuck or power universal pin driver to back out and remove the Anser Clavicle Pin.
- 11.** Verify complete removal of hardware by means of fluoroscopy in two directions.
- 12.** Irrigate the surgical field and close the incision. Apply dressing.

References

Literature

1. Nowak J, Holgersson M, Larsson S. Sequelae from clavicular fractures are common: a prospective study of 222 patients. *Acta Orthop* 2005; 76(4):496-502.
2. Robinson CM. Fractures of the clavicle in the adult. Epidemiology and classification. *J Bone Joint Surg Br* 1998; 80(3):476-84.
3. Ledger M, Leeks N, Ackland T, Wang A. Short malunions of the clavicle: an anatomic and functional study. *J Shoulder Elbow Surg* 2005; 14(4):349-54.
4. Jørgensen A, Troelsen A, Ban I. Predictors associated with nonunion and symptomatic malunion following non-operative treatment of displaced midshaft clavicle fractures—a systematic review of the literature. *International Orthopaedics* 2014; Jul 16 DOI 10.1007/s00264-014-2450-7.
5. Hill JM, McGuire MH. Closed treatment of displaced middle-third fractures of the clavicle gives poor results. *J Bone Joint Surg Br* 1997; 79:537-539.
6. Canadian Orthopaedic Trauma Society. Nonoperative treatment compared with plate fixation of displaced midshaft clavicular fractures. A multicenter, randomized clinical trial. *J Bone Joint Surg Am.* 2007 Jan;89(1):1-10.
7. Lenza M, Faloppa F. Surgical interventions for treating acute fractures or non-union of the middle third of the clavicle. *Cochrane Database Syst Rev.* 2015 May 7;5:CD007428. doi: 10.1002/14651858.CD007428.pub3. Review.
8. Kleweno CP1, Jawa A, Wells JH, O'Brien TG, Higgins LD, Harris MB, Warner JJ. Midshaft clavicular fractures: comparison of intramedullary pin and plate fixation. *J Shoulder Elbow Surg.* 2011 Oct;20(7):1114-7. doi: 10.1016/j.jse.2011.03.022. Epub 2011 Jul 1.
9. Fu TH1, Tan BL, Liu HC, Wang JW. Anatomical reduction for treatment of displaced midshaft clavicular fractures: Knowles pinning vs. reconstruction plating. *Orthopedics.* 2012 Jan 16;35(1):e23-30. doi: 10.3928/01477447-20111122-05.
10. Marlow WJ, Ralte P, Morapudi SP, Bassi R, Fischer J, Waseem M. Intramedullary fixation of diaphyseal clavicle fractures using the rockwood clavicle pin: review of 86 cases. *Open Orthop J.* 2012;6:482-7. doi: 10.2174/1874325001206010482. Epub 2012 Nov 16. PubMed PMID: 23173024; PubMed Central PMCID: PMC3502893.
11. Ferran NA, Hodgson P, Vannet N, Williams R, Evans RO. Locked intramedullary fixation vs plating for displaced and shortened mid-shaft clavicle fractures. *J Shoulder Elbow Surg.* 2010 Sep;19(6):783-9. doi: 10.1016/j.jse.2010.05.002.
12. Millet PJ, Hurst JM, Horan MP, Hawkins RJ. Complications of clavicle fractures treated with intramedullary fixation. *Journal of Shoulder and Elbow Surgery.* 2011 Oct; 20.
13. Chen QY, Kou DQ, Cheng XJ, Zhang W, Wang W, Lin ZQ, Cheng SW, Shen Y, Ying XZ, Peng L, Lv CZ. Intramedullary nailing of clavicular midshaft fractures in adults using titanium elastic nail. *Chin J Traumatol.* 2011;14(5):269-76. PubMed PMID: 22118480.
14. Kadakia AP, Rambani R, Qamar F, McCoy S, Koch L, Venkateswaran B. Titanium elastic stable intramedullary nailing of displaced midshaft clavicle fractures: A review of 38 cases. *Int J Shoulder Surg.* 2012 Jul;6(3):82-5. doi: 10.4103/0973-6042.102557. PubMed PMID: 23204762; PubMed Central PMCID: PMC3507328.
15. Braun KF, Siebenlist S, Sandmann GH, Martetschläger F, Kraus T, Schrödl C, Kirchhoff C, Neumaier M. Functional results following titanium elastic-stable intramedullary nailing (ESIN) of mid-shaft clavicle fractures. *Acta Chir Orthop Traumatol Cech.* 2014;81(2):118-21. PubMed PMID: 25105785.
16. Frigg A, Rillmann P, Ryf C, Glaab R, Reissner L. Can complications of titanium elastic nailing with end cap for clavicular fractures be reduced? *Clin Orthop Relat Res.* 2011 Dec;469(12):3356-63. doi: 10.1007/s11999-011-1845-7. PubMed PMID: 21409459; PubMed Central PMCID: PMC3210265.
17. Mueller M, Rangger C, Striepens N, Burger C. Minimally invasive intramedullary nailing of midshaft clavicular fractures using titanium elastic nails. *J Trauma.* 2008 Jun;64(6):1528-34. doi: 10.1097/TA.0b013e3180d0a8bf. PubMed PMID: 18545118.
18. Müller MC, Burger C, Florczyk A, Striepens N, Rangger C. [Elastic titanium nails in minimally invasive osteosynthesis for mid-clavicular fractures]. *Chirurg.* 2007 Apr;78(4):349-55. German. PubMed PMID: 17151840.
19. Narsaria N, Singh AK, Arun GR, Seth RR. Surgical fixation of displaced midshaft clavicle fractures: elastic intramedullary nailing versus precontoured plating. *J Orthop Traumatol.* 2014 Sep;15(3):165-71. doi: 10.1007/s10195-014-0298-7. Epub 2014 May 25. PubMed PMID: 24859367; PubMed Central PMCID: PMC4182648.
20. Saha P, Datta P, Ayan S, Garg AK, Bandyopadhyay U, Kundu S. Plate versus titanium elastic nail in treatment of displaced midshaft clavicle fractures: A comparative study. *Indian J Orthop.* 2014 Nov;48(6):587-93. doi: 10.4103/0019-5413.144227. PubMed PMID: 25404771; PubMed Central PMCID: PMC4232828.
21. Jubel A, Andermahr J, Schiffer G, Tsironis K, Rehm KE. Elastic stable intramedullary nailing of midclavicular fractures with a titanium nail. *Clin Orthop Relat Res.* 2003 Mar;408:279-85. PubMed PMID: 12616071.

22. Assobhi JE. Reconstruction plate versus minimal invasive retrograde titanium elastic nail fixation for displaced midclavicular fractures. J Orthop Traumatol. 2011 Dec;12(4):185-92. doi: 10.1007/s10195-011-0158-7. Epub 2011 Sep 27. PubMed PMID: 21948051; PubMed Central PMCID: PMC3225608.
23. Walz M, Kolbow B, Auerbach F. [Elastic, stable intramedullary nailing in midclavicular fractures—a change in treatment strategies?]. Unfallchirurg. 2006 Mar;109(3):200-11. German. PubMed PMID: 16308678.
24. Kraus TM, Martetschläger F, Schrödl C, Siebenlist S, Ganslmeier A, Kirchoff C, Stöckle U. [Elastic stable intramedullary nailing of clavicular midshaft fractures: comparison of open vs closed fracture reduction]. Unfallchirurg. 2013 Feb;116(2):102, 104-8. doi: 10.1007/s00113-011-2059-x. German. PubMed PMID: 21691780.
25. Hoogervorst P, van Dam T, Verdonschot N, Hannink G. Functional outcomes and complications of intramedullary fixation devices for Midshaft clavicle fractures: a systematic review and meta-analysis. BMC Musculoskelet Disord. 2020 Jun 22;21(1):395. doi: 10.1186/s12891-020-03256-8. PMID: 32571362; PMCID: PMC7310279.
26. Hoogervorst P, Konings P, Hannink G, Holla M, Schreurs W, Verdonschot N, van Kampen A. Functional outcomes, union rate, and complications of the Anser Clavicle Pin at 1 year: a novel intramedullary device in managing midshaft clavicle fractures. JSES Int. 2020 Mar 4;4(2):272-279. doi: 10.1016/j.jseint.2020.01.002. PMID: 32490413; PMCID: PMC7256888.

Figures

Figure 1, 2: Adopted from AO Surgery Reference website <https://www2.aofoundation.org/wps/portal/surgery>

All other figures supplied by Anser Implants BV



BAAT Medical Products B.V.
F. Hazemeijerstraat 800
7555 RJ Hengelo
The Netherlands
Phone: +31 (0)88 565 66 00
www.baatmedical.com

| REF | Name |
|-----------|--|
| ANS-501S | Anser Clavicle Pin Set |
| ANS-602 | Anser Manual Pin Driver |
| ANS-603 | Anser Tap |
| ANS-604 | Anser Lateral Fixation Device Inserter |
| ANS-605 | Anser End Cap Inserter |
| ANS-701 | Anser Tray |
| 310.401 | Drill Bit |
| 95-186.01 | Drill Guide |

